

PSEUDOMEMBRANEOUS GASTRITIS COMPATIBLE WITH (*Clostridium* sp.) IN A CAPTIVE PEREGRINE FALCON

JAMES H. ENDERSON AND MORGAN BERTHRONG, M.D.

ABSTRACT - There have been several instances where the Peregrine Falcon (*FALCO PEREGRINUS*) used for captive-breeding for many years have died rapidly after being removed from the breeding lofts (W. Burnham, J. Weaver, C. White pers. comm.). This is an account of such an instance where the benefit of a complete necropsy is available and reveals one possible explanation for these losses.

A female Peregrine in captivity over 19 y had produced nearly 100 eggs during the last 10 y while in the loft with a male. Because no eggs were produced in the last year the bird was hooded and transported to a new location. She appeared calm after subsequently consuming a portion of a thawed quail. She seemed relaxed and normal the next morning, but at 1000 h was lethargic. By 1200 h she was breathing heavily and rapidly, and was very weak. She died within the hour.

PATHOLOGIC OBSERVATIONS

Complete autopsy revealed a good state of nutrition. Body weight was 860g. The lateral air sacs were smooth and glistening without parasitic worms or fungi. The oral cavity, crop, esophagus, trachea, lungs and heart were entirely normal. The stomach was empty and contracted with resulting thickening of its mucosal folds. A gray-green exudate was adherent to the mucosal surface. No ulcerations were noted. The remainder of the intestinal tract was grossly normal. The adrenal glands were smaller in comparison to a wild peregrine. The spleen was slightly enlarged. The ovary was small and nodular without developing ova. The kidneys, pancreas, and brain appeared grossly normal.

Histologic examination revealed a fibrinopurulent layer which covered the gastric mucosa where only the most superficial mucosal cells were necrotic and only a superficial mucosal infiltrate of inflammatory cells was observed. The mucosal capillaries were dilated. Gram stains revealed swarms of gram positive rods, large, straight with slightly rounded ends and numerous oval subterminal and central spores, characteristic of a clostridial species within the fibrinopurulent membrane (Fig. 1 and 2). These organisms were not found in the mucosa itself or in the muscularis of the stomach. Large numbers of bacilli, mostly gram positive and similar to those in the stomach, were found in the lumina of both small and large intestine but no mucosal alterations or pseudomembranes were seen. The spleen

showed plasmacytoid cells in the red pulp consistent with an immunologic reaction, a so-called "acute splenic tumor".

Kidney sections showed small cysts of a possible congenital cystic disease but large areas of normal glomeruli and tubules suggested normal renal sufficiency. Minimal osteoarthritis was found in the upper humeral joint surface. A small para-adrenal microscopic nodule was found, thought to be a benign neoplasm resembling a human neoplasm known as a carcinoid. Several cysts were found in one of a number of sections of skeletal muscle recognized as those of quiescent avian malaria, possibly *Plasmodium relictum*. These cysts were not surrounded by any tissue reaction and the liver, spleen, bone marrow and heart showed no evidence of active malaria.

DISCUSSION

The development of a pseudomembranous enterocolitis of the intestinal tract with toxic shock, often fatal, has been well recognized in man (Goulston et al. 1965). It was known to occur during the post-operative period, usually after abdominal surgery, before the advent of antibiotics. Presumably because of an alteration of the bacterial environment, pseudomembranous enteritis or colitis became much more common after widespread use of antibacterial agents in man. At first, cases may have been the result of highly virulent staphylococci but in recent years evidence indicates that most human cases are now the result of overgrowth of clostridial species in the gastrointestinal tract (Bartlett et al. 1978). Epidemics of this condition occurred in Germany immediately after World War II (MacLenan 1962), and in New Guinea (Murrell et al. 1966) from *Clostridium perfringens*, presumably due to ingestion of food massively contaminated with this organism. Recently, most human cases have been shown to be the result of overgrowth of the antibiotic-resistant *Clostridium difficile*, the exotoxin of which has a potent cytotoxic effect and

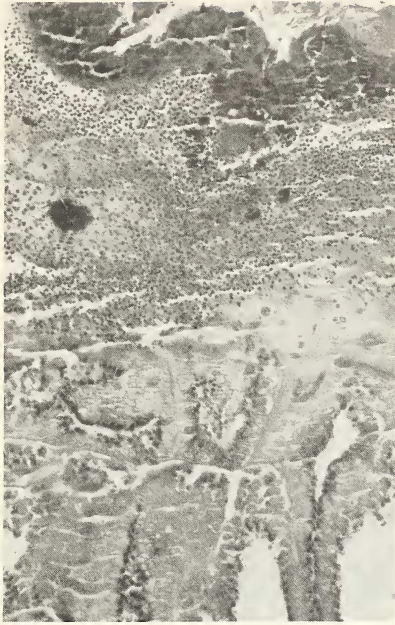


Figure 1. Low power photomicrograph of gastric mucosa covered by a fibrinopurulent pseudomembrane containing swarms of bacteria but with only superficial erosion of the glands.

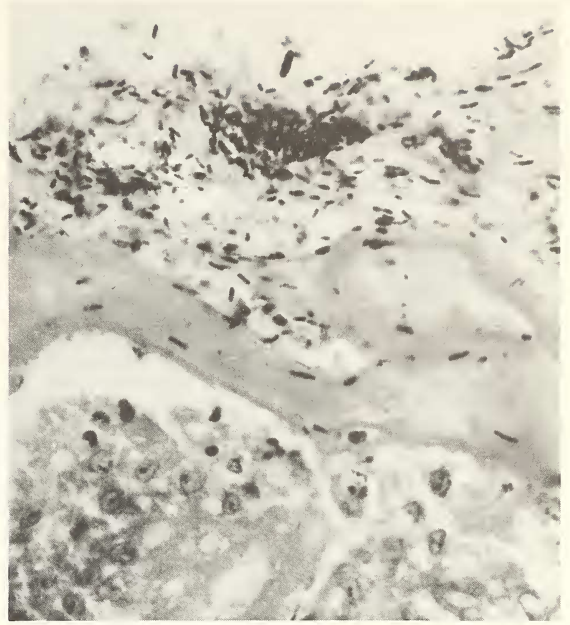


Figure 2. High power photomicrograph of the pseudomembrane with large grampositive rods characteristic of a clostridial species.

after absorption has frequently lethal action (George et al. 1978). Most human cases are seen in patients on antibiotics, after serious surgical procedures, in newborn infants, and in patients in whom, for many different reasons, immunosuppression exists. Essentially identical pseudomembranous enterocolitis can be produced experimentally in rabbits (Kata et al. 1978) and hamsters (Rifkin et al. 1978). This falcon developed acute pseudomembranous gastritis histopathologically identical to human cases. That the bird died of resulting clostridial toxemia is suggested although not confirmed by culturing the suspected etiologic agent. It is possible the falcon ingested food with large numbers of clostridial organisms, a bacterium known to multiply with great rapidity under proper circumstances and that the stress of moving led to the rapid growth of those organisms in the gastrointestinal tract resulting in pseudomembranous gastritis. It is of interest that some birds and mammals are known to carry *C. difficile* in the intestinal track (McBee 1960).

Of some clinical importance, while most clostridial species are susceptible to penicillin, *C. difficile* is

sensitive only to Vancomycin. Furthermore, the oral administration of cholestyramine resin, which apparently binds the toxin in the lumen of the gut, has proven efficacious in human cases of pseudomembranous gastrointestinal disease due to *Clostridium difficile* (Kreutzer and Mulligan 1978).

LITERATURE CITED

- BARTLETT, J.G., CHANG, T.W., GURWITH, M., GORBACH, S.L. AND ONDERDONK, A.B. 1978. Antibiotic-associated pseudomembranous colitis due to toxic producing *Clostridia*. *N. Eng. J. Med.* 298:531-4.
- GEORGE, R.H., SYMONDS, J.M., DOMOCK, F., ET AL. 1978. Identification of *Clostridium difficile* as a cause of pseudomembranous colitis. *Brit. Med. J.* 1:695.
- GOULSTON, S.J.M. AND V.J. MCGOVERN. 1965. Pseudomembranous colitis. *Gut* 6:207-212.
- KATZ, L., J.T. LAMONT, J.S. TRIER, E.B. SOUNENBLICK, S.W. ROTHMAN, S.A. BROITMAN AND S. RIETH. 1978. Experimental Clindamycin-associated colitis in rabbits. *Gastroent.* 74:246-252.

- KREUTZER, E.W. AND F.D. MULLIGAN. 1978. The treatment of antibiotic-associated pseudomembranous colitis with cholestyramine resin. *The Johns Hopkins Medical Journal* 143:67-72.
- MACLENNAN, J.D. 1962. The histotoxic Clostridial infections of man. *Bac. Rev.* 26:177-276.
- MCBEE, R.H. 1960. Intestinal flora of some Antarctic birds and mammals. *J. Bacteriology* 79:311-312.
- MURRELL, T.G.C., L. ROTH, J. EGERTON AND P.D. WALKER. 1966. Pigbel: enteritis necroticans. *Lancet* 1:217-222.
- RIFKIN, G.D., J. SILVA AND R. FEKETY. 1978. Gastrointestinal and systemic toxicity of fecal extracts from hamsters with clindamycin-induced colitis. *Gastroent* 74:52-57.

Department of Biology, The Colorado College, Colorado Springs, CO 80903. Address of second author: Penrose Hospital, 2215 N. Cascade Ave., Colorado Springs, CO 88907.

Received 12 November 1983; Accepted 15 August 1984

BIOTELEMETERED DAILY HEART RATE CYCLES IN THE RED-TAILED HAWK (*Buteo jamaicensis*)

DAVID E. BUSCH, WILLIAM A. DEGRAW AND N.C. CLAMPITT

ABSTRACT - Daily fluctuations in resting heart rate (HR) were studied in a captive ♀ Red-tailed Hawk (*Buteo jamaicensis*) using radiotelemetry. HR's were recorded hourly during 10 consecutive days while the hawk was housed in an outdoor pen. Daytime HR's averaged 202 beats/min and were significantly higher than the average nocturnal HR of 134 beats/min ($P < 0.001$). Maximum HR's (> 200 beats/min) occurred crepuscularly, just after sunrise and before sunset.

Daily cycles of several physiological factors have long been known for a number of birds and mammals. In birds for example, marked nocturnal depression of body temperature has been demonstrated in Snowy Owls (*Nyctea scandiaca*) and Short-eared Owls (*Asio flammeus*) by Irving (1955). Odum (1941) commented on the marked changes in heart rate (HR) occurring between day and night in avian species. Smith et al. (1976) reported that telemetered HR is lower and less variable during darkness in the domestic Mallard Duck (*Anas platyrhynchos*). One method, that of telemetered HR, allows physiological study of unrestrained birds under near-natural conditions. This method has also been promoted as a suitable indicator of relative metabolic rate in homeotherms (Johnson and Gessaman 1973; Gessaman 1980).

Indications that HR can be a good relative metabolic indicator come from studies in which HR and O_2 consumption were measured simultaneously (Morhardt and Morhardt 1971; Lund and Folk 1976). Similarities between HR-ambient temperature curves and metabolism-ambient temperature curves have been demonstrated for birds such as the Burrowing Owl (*Athene cunicularia*) (Coulombe 1970) and Blue-winged Teal (*Anas dis-*

cors) (Owen 1969). Because of circulatory adjustments occurring during more intense locomotor activity, HR is only considered a valid metabolic indicator when an animal is unstressed and at rest, or exercising moderately (Jones and Wang 1976). We have used telemetered HR's to demonstrate stress in the Ferruginous Hawk (*Buteo regalis*) (Busch et al. 1978), but in order to use HR as a metabolic indicator, activity levels must be low and stress minimal.

Little of the aforementioned types of research have focused on birds of prey in spite of the emphasis on raptor conservation, rehabilitation and captive breeding. Our goal was to assess diurnal fluctuations in resting HR's of the Red-tailed Hawk via telemetry. Changes in HR were also compared with time of day and with extrinsic factors such as ambient temperature and elevation of the sun.

METHODS

The subject of this study, a ♀ Red-tailed Hawk, was considered non-releasable by rehabilitation personnel because of an unmendable broken wing. This disability did not conflict with the study's goals since the bird's feeding and perching were not affected, and since our focus was on daily variations in resting HR.

The hawk was maintained in an outdoor pen measuring 56 m²